

Patient: [REDACTED]
Patient ID: ---
Diagnosis: ---

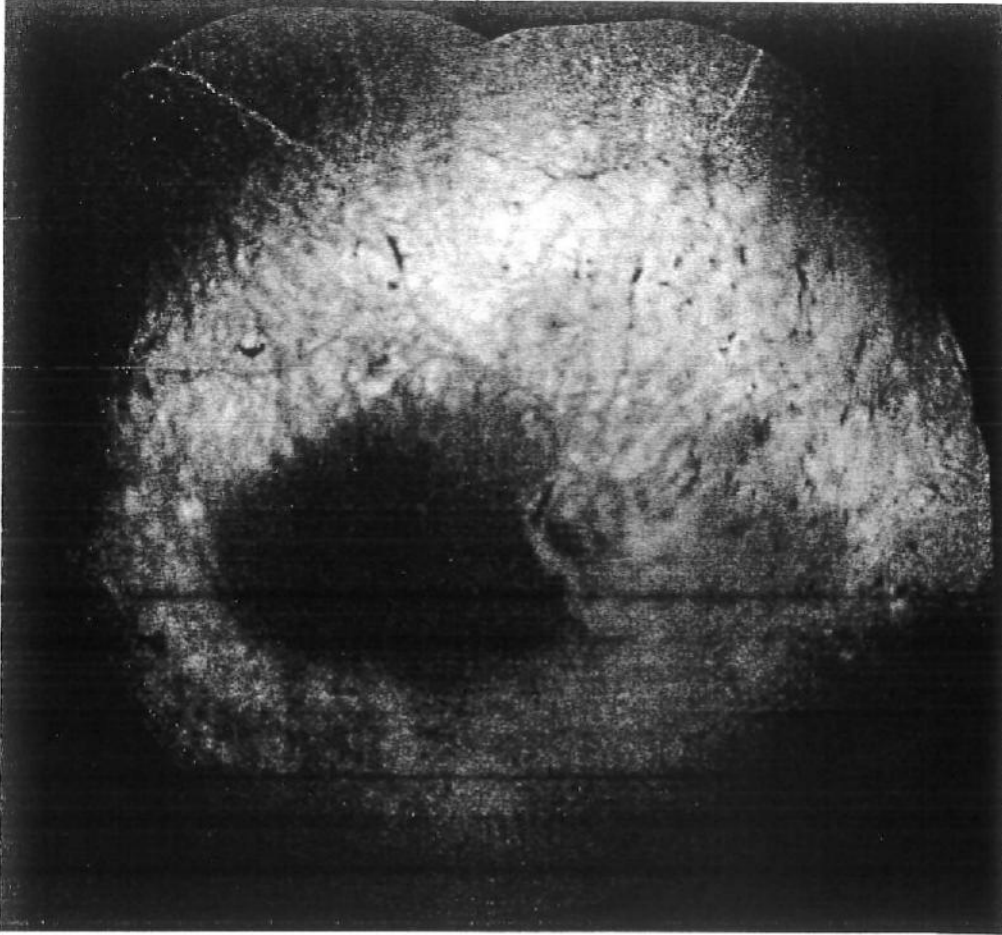
DOB: [REDACTED]
Exam.: 23/mar/2021
Comment: ---

Sex: M

*Proz
ermatte*

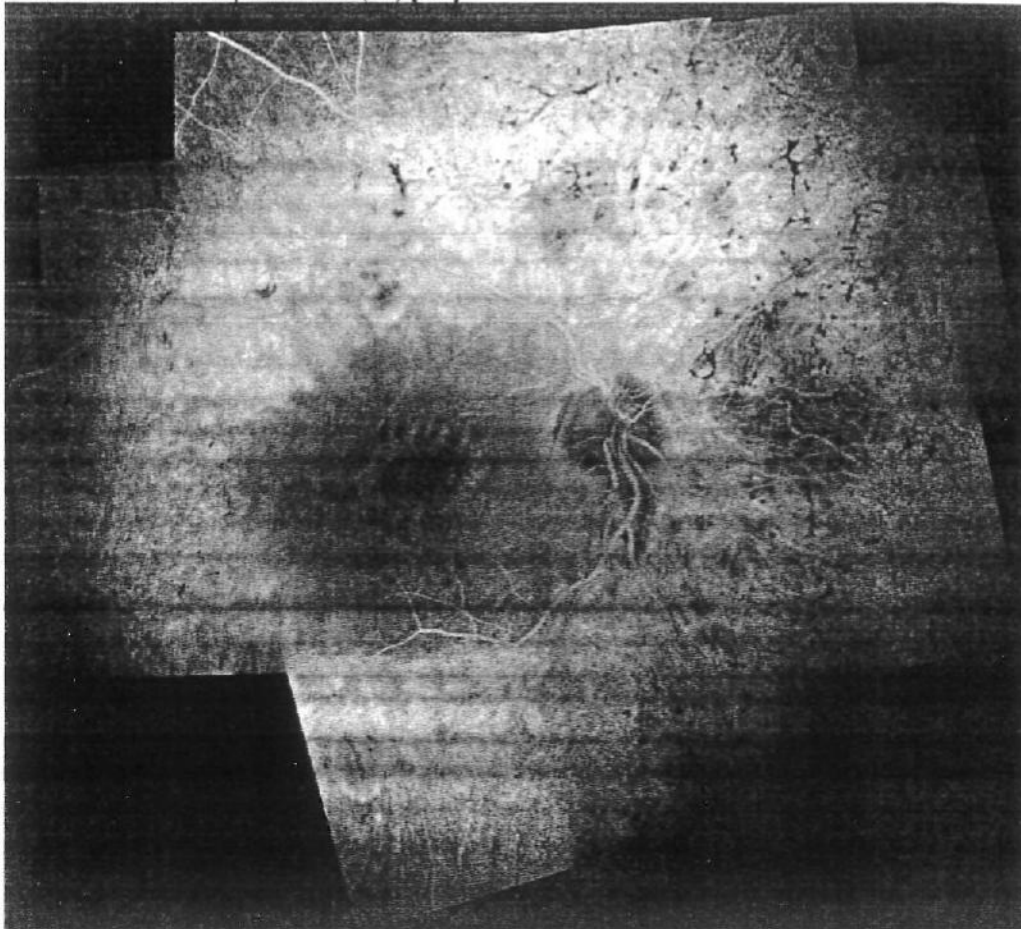
OD

FA 8:18.16 55° ART Comp. 86°x77° ([HS])



[REDACTED]
[Signature]

FA 0:31.15 30° Comp. 85°x75° (19) [HS]



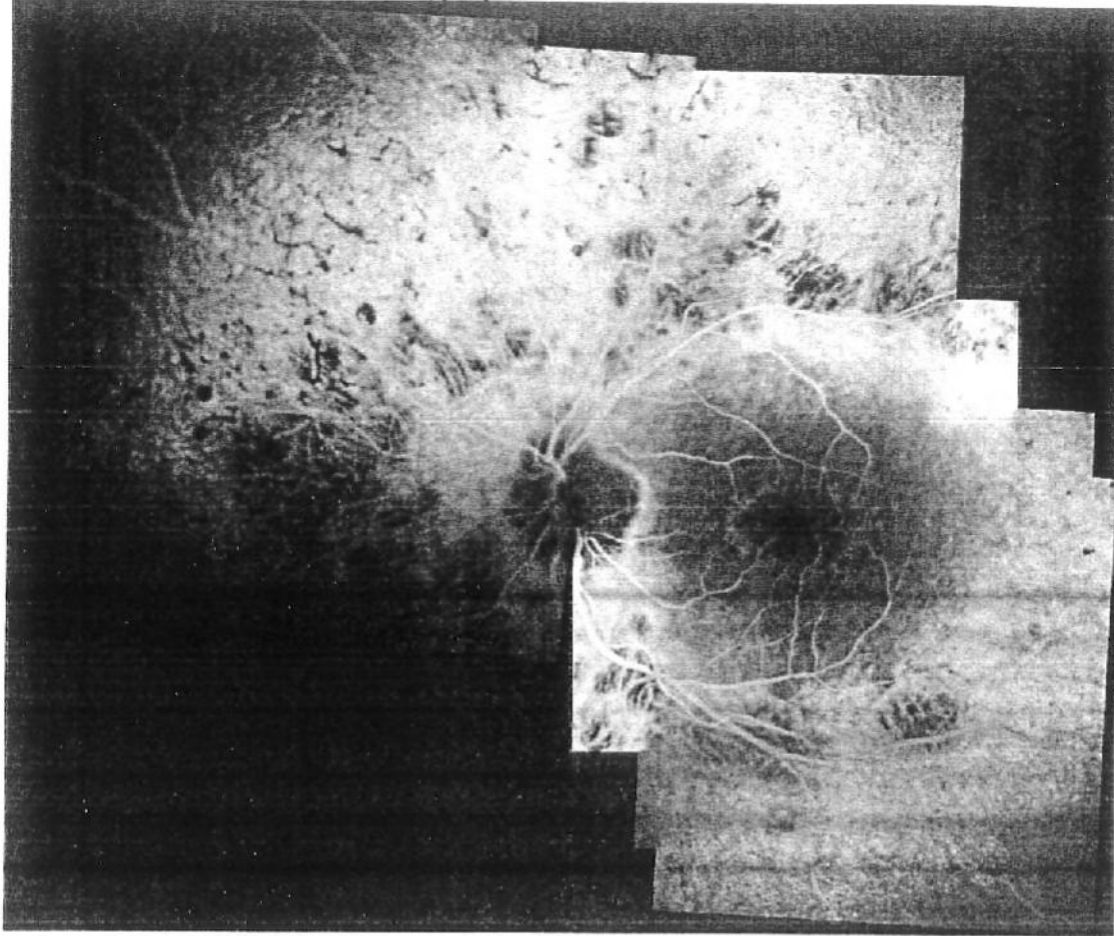
Patient: [REDACTED]
Patient ID: ---
Diagnosis: ---

DOB: [REDACTED]
Exam.: 23/mar/2021
Comment: ---

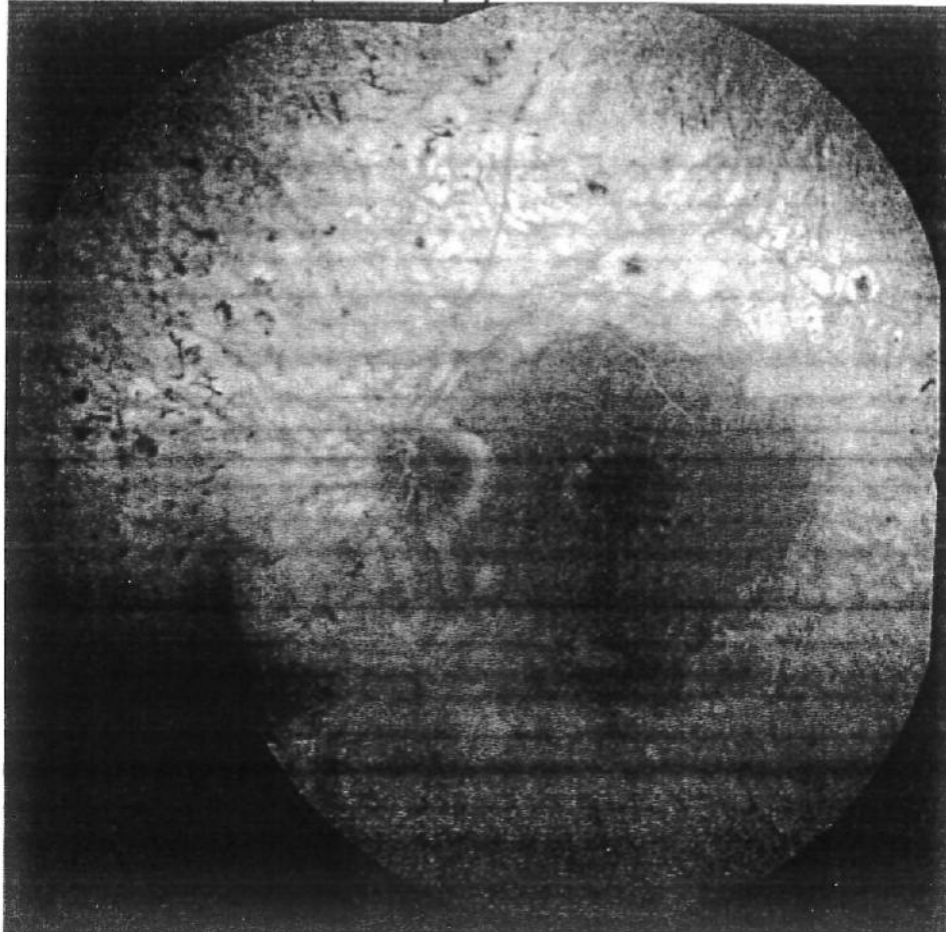
Sex: M

OS

FA 0:41.44 30° ART Comp. 75°x61° [HS]



FA 10:20.84 55° ART Comp. 73°x70° [HS]



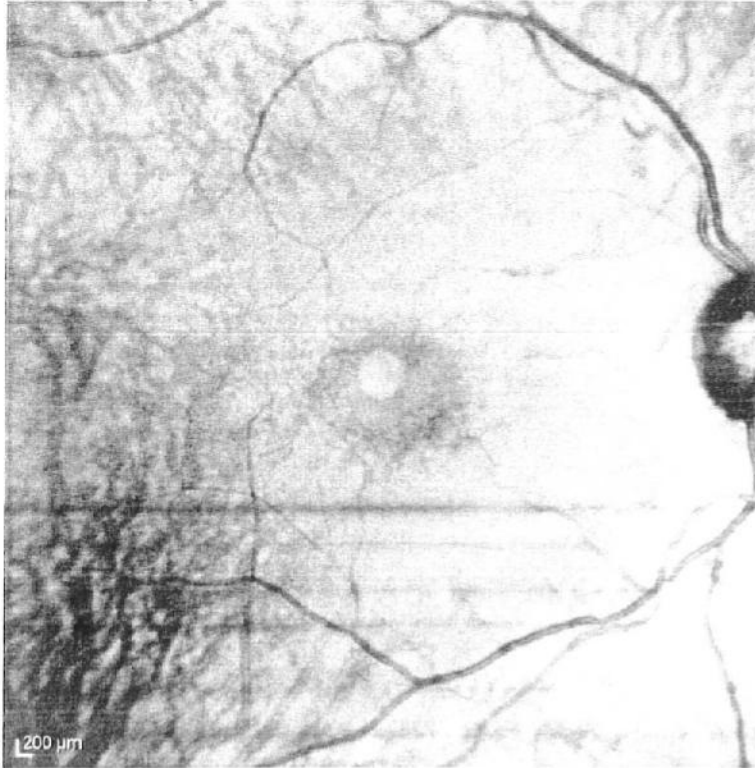
Patient: [REDACTED]
Patient ID: ---
Diagnosis: ---

DOB: [REDACTED]
Exam.: 23/mar/2021
Comment: ---

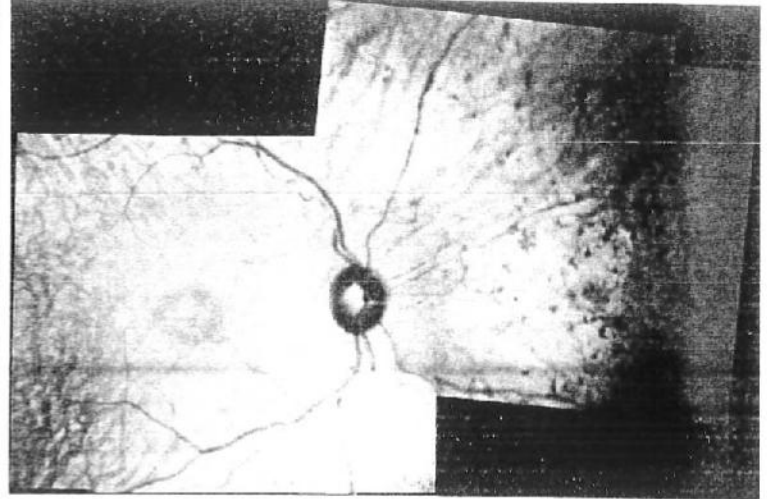
Sex: M

OD

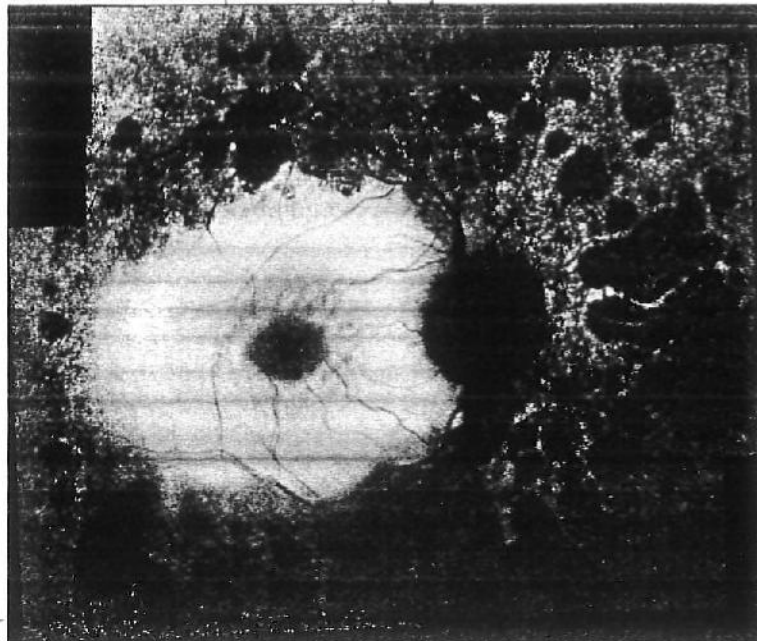
IR 30° ART [HS]




IR 30° Comp. 64°x42° (5) [HS]



BAF 30° ART Comp. 56°x46° (7) [HS]



FA 12:06:68 30° ART [HS]



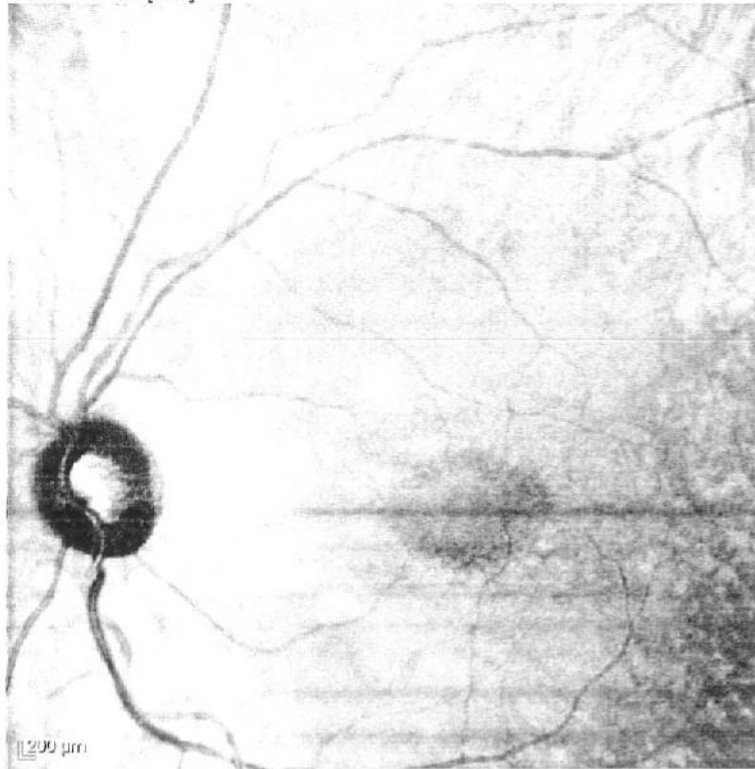
Patient: [REDACTED]
Patient ID: ---
Diagnosis: ---

DOB: [REDACTED]
Exam.: 23/mar/2021
Comment: ---

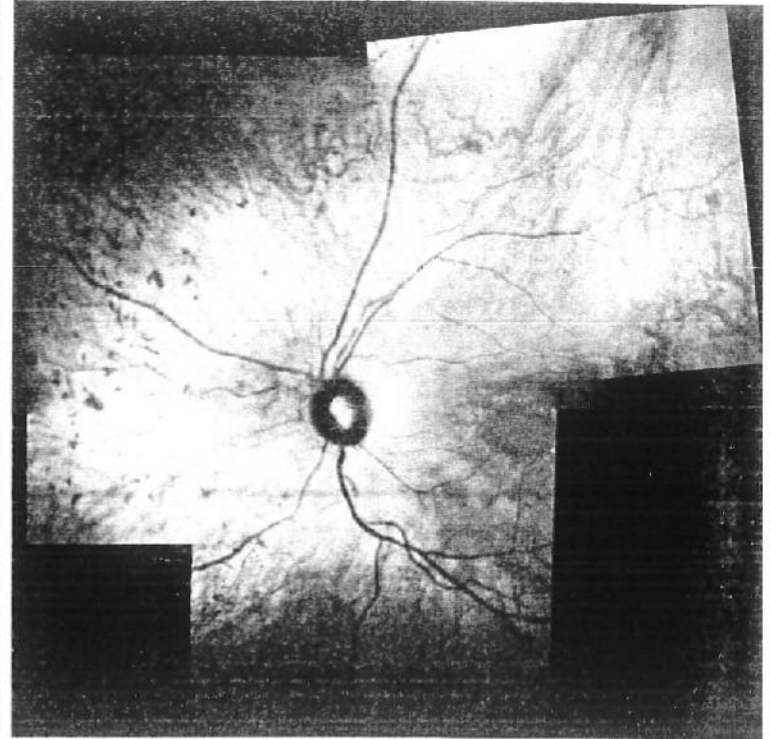
Sex: M

OS

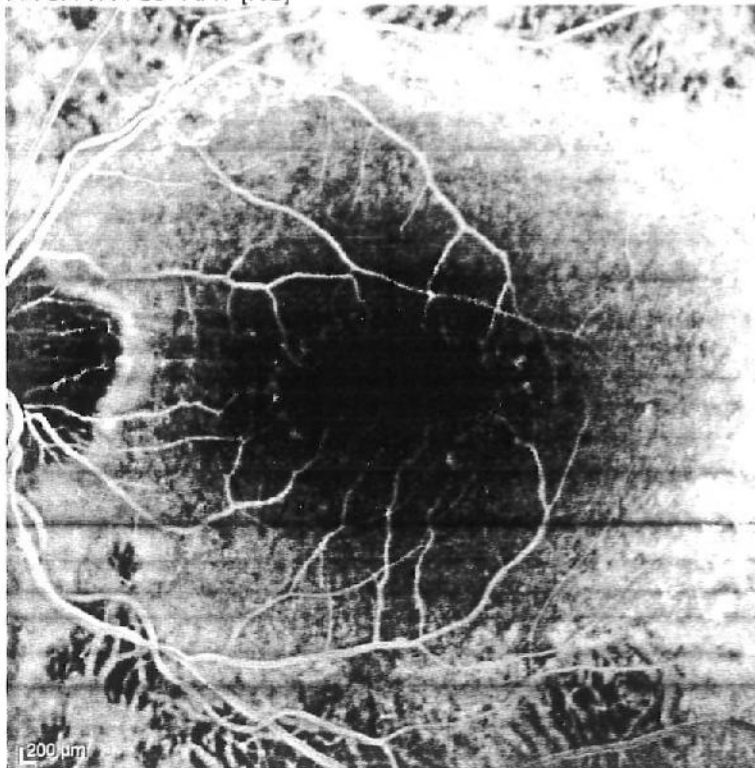
IR 30° ART [HS]



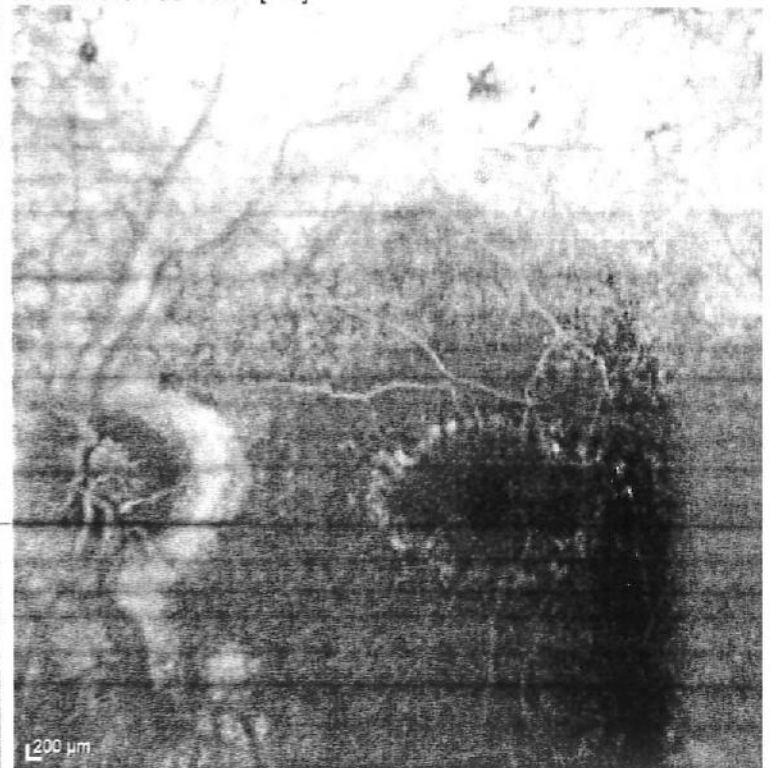IR 30° ART Comp. 62°x60° (7) [HS]



FA 0:41.44 30° ART [HS]



FA 12:17.64 30° ART [HS]

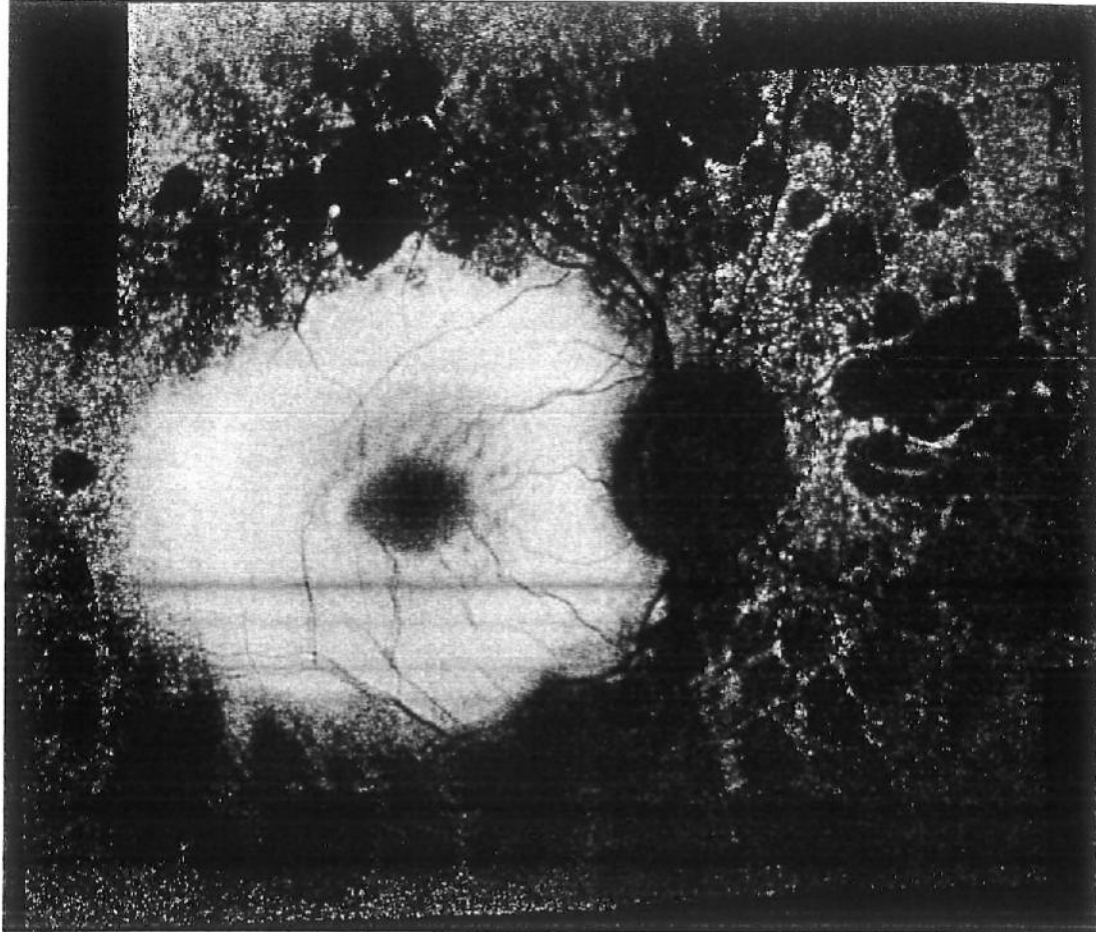


Patient: [REDACTED]
Patient ID: ---
Diagnosis: ---

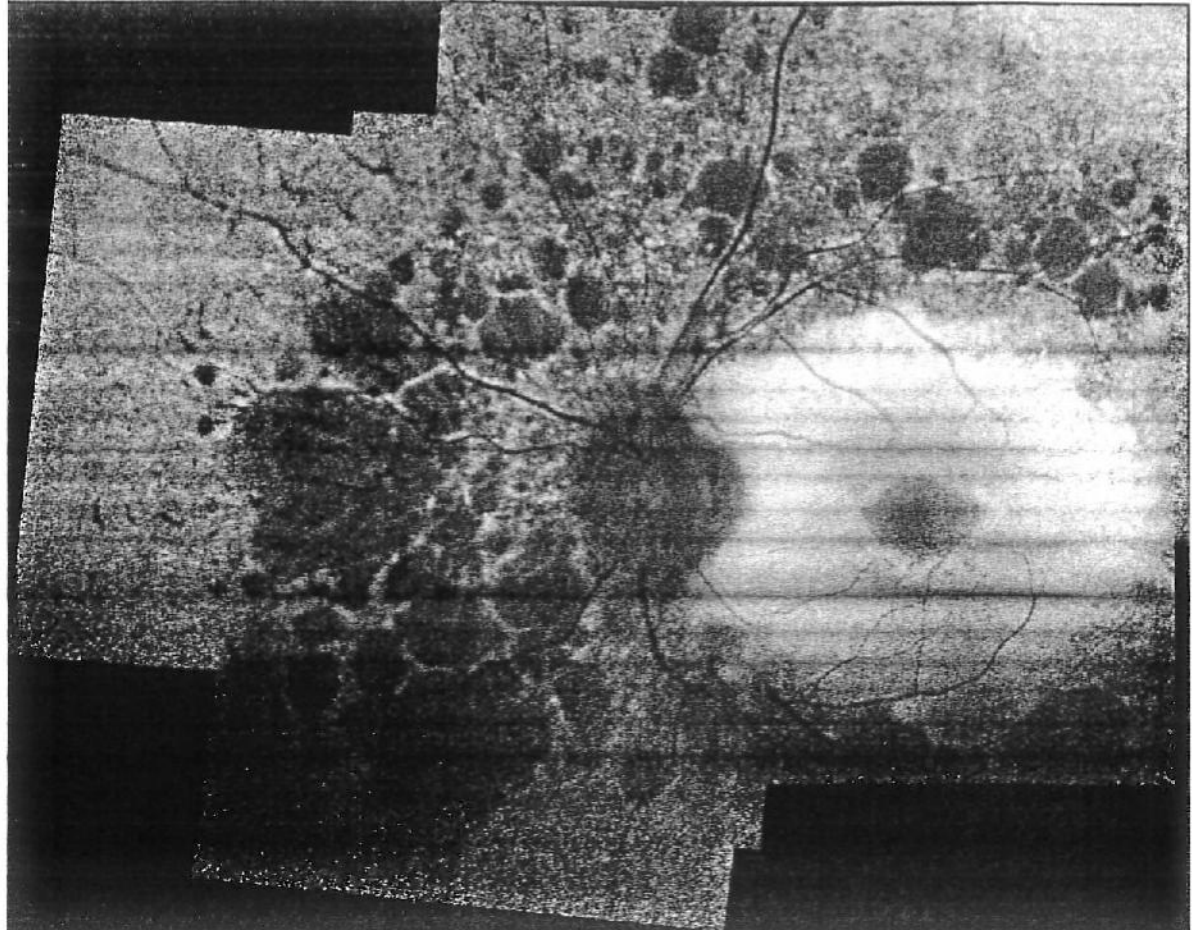
DOB: [REDACTED]
Exam.: 23/mar/2021
Comment: ---

Sex: M

OD, BAF 30° ART Comp. 56°x46° (7) [HS]

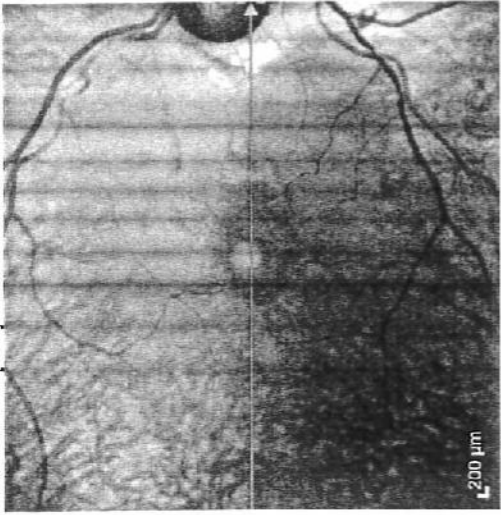


OS, BAF 30° ART Comp. 67°x52° (12) [HS]

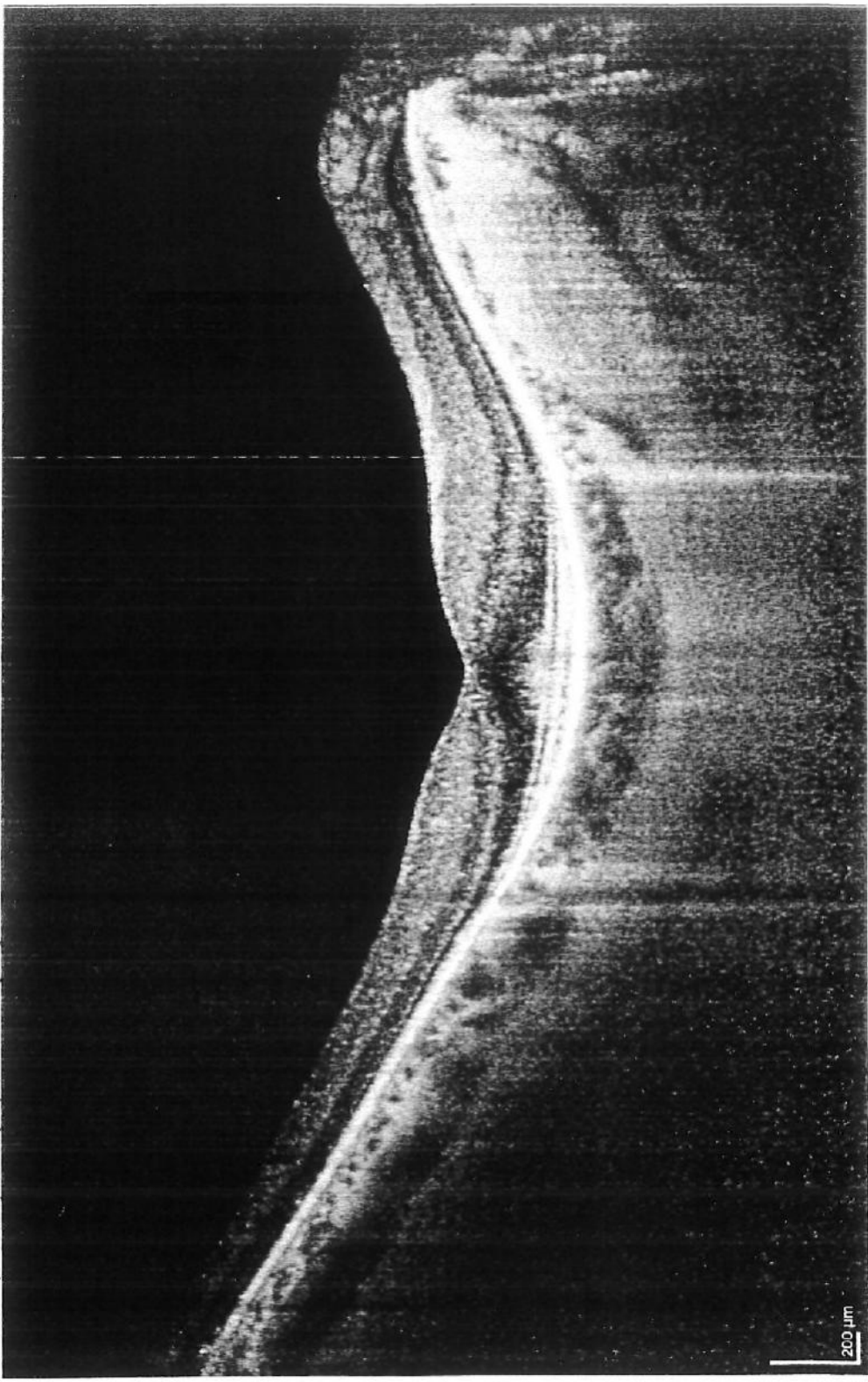


Patient: [REDACTED] Sex: M
 Patient ID: --- DOB: [REDACTED]
 Diagnosis: --- Exam.: 23/mar/2021
 Comment: ---

IR 30° ART [HS]



OCT 30° (8.7 mm) ART (14) Q: 36 EDI [HS]



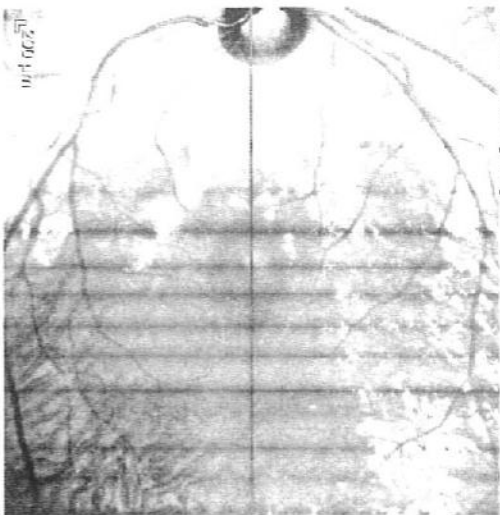
Detailed Report
SPECTRALIS® Tracking Laser Tomography

Patient: [REDACTED]
Patient ID: ---
Diagnosis: ---

DOB: [REDACTED]
Exam.: 23/mar/2021
Comment: ---

Sex: M

IR 30° ART [HS]



OCT 30° (8.7 mm) ART (21) Q: 39 EDI [HS]

