

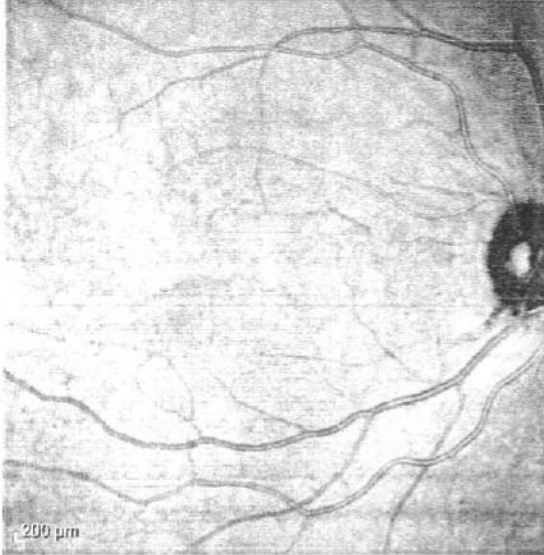
PROVA PRATICA "S"
PDA non esente
OD

Patient: [REDACTED]
Patient ID: ---
Diagnosis: ---

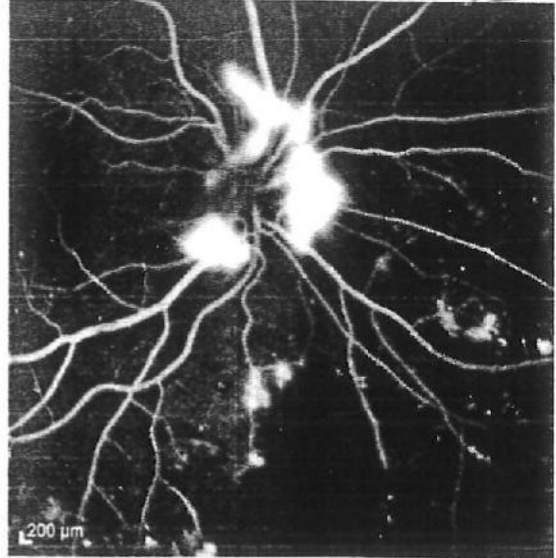
DOB: [REDACTED]
Exam.: 10/lug/2018
Comment: ---

Sex: [REDACTED]

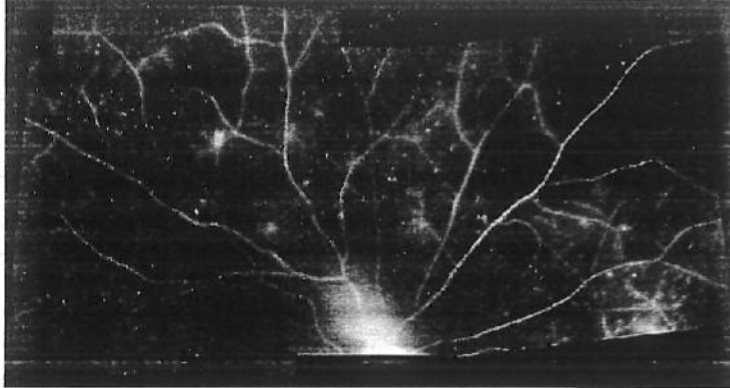
IR 30° [HS]



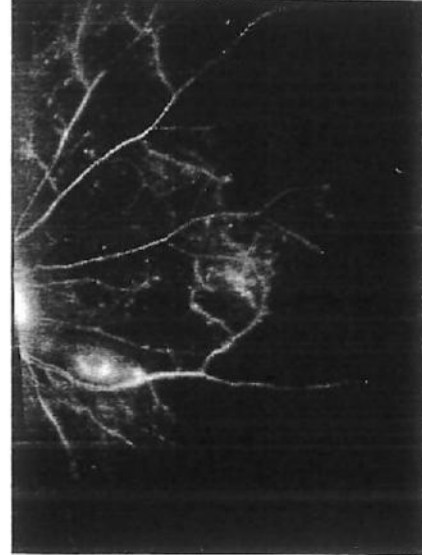
FA 0:32.34 30° [HS]



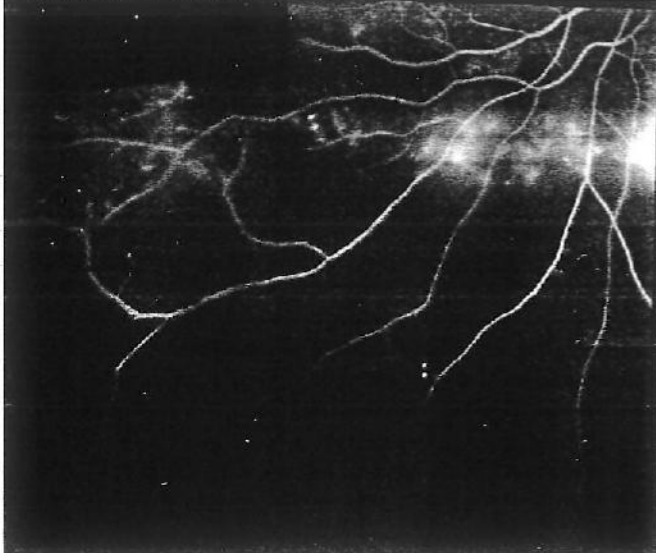FA Composite 75°x39° (8) [HS]



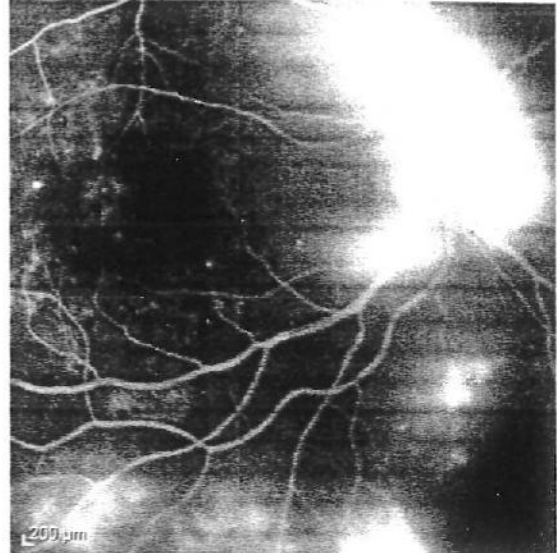
FA Composite 43°x57° (8) [HS]



FA Composite 53°x44° (19) [HS]



FA 5:32.14 30° [HS]



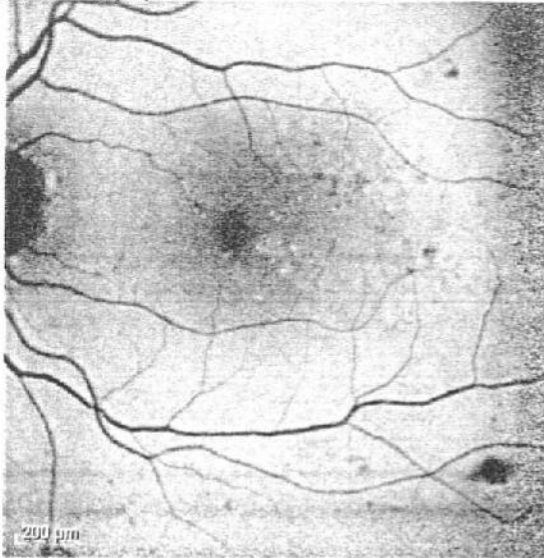
Patient: [REDACTED]
Patient ID: ---
Diagnosis: ---

DOB: [REDACTED]
Exam.: 10/lug/2018
Comment: ---

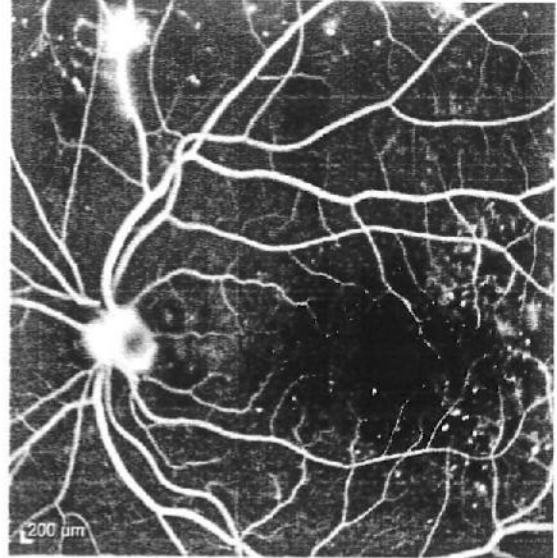
Sex: M

OS

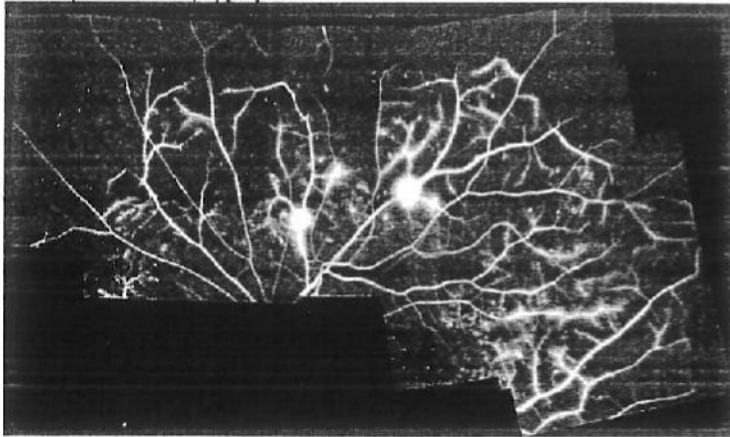
BAF 30° ART [HS]



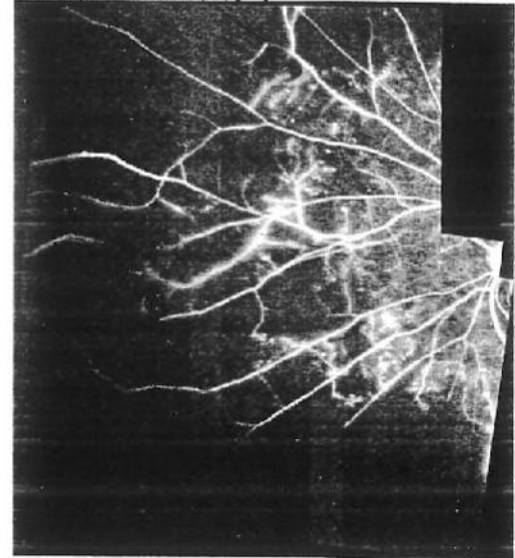
FA 0:49.07 30° [HS]



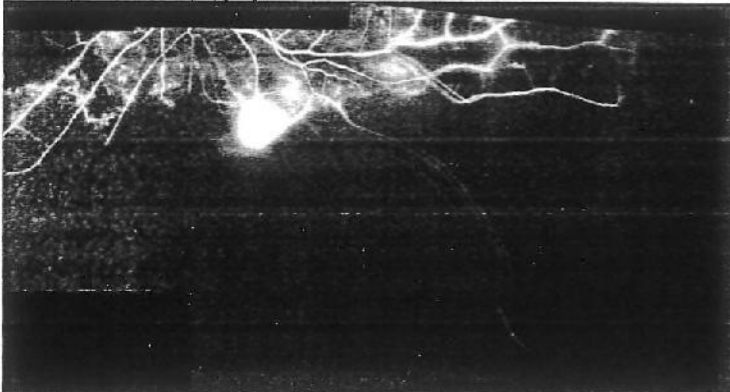
FA Composite 99°x57° (14) [HS]



FA Composite 54°x59° (11) [HS]



FA Composite 87°x45° (13) [HS]



FA 5:38.81 30° [HS]

